

# Focus on Dental Caries Management — Beyond Extension for Prevention to Minimal Intervention

*Stephen H. Abrams, DDS, FADI (Hon.), FPFA (Hon.); Margaret I. Scarlett, DMD and Lori Trost, DMD*

Dr. G.V. Black would be pleased about today's new techniques, as he would be in his place of honor at the National Museum of Dentistry. Faced with limited choices, he had to design cavity preparations in an era where carious lesions were more advanced than in today's fluoridated world. He had to use materials invented about the same time as the steel in his black Model T Ford. In contrast, today's minimally invasive restorative techniques are solidly based on changes in diagnostic equipment, restorative materials, and our current understanding of the biology of caries.

Just like choices beyond black in today's cars, we have a plethora of new materials and choices to make over those of Dr. G.V. Black's time. Instead of "extension for prevention," today's cavity preparation is designed to preserve the health of the tooth over a lifetime. Minimally invasive dentistry is the adoption of detection, diagnosis, limited surgical intervention for excavation of

decay, and restoration, with a view toward maximum preservation of tooth structure and adjunctive remineralization therapy.<sup>1</sup> This is the context of the new philosophy of dental caries management.

This is the third article in a three-part series on caries management. Previous articles have focused on the etiology of caries and caries assessment techniques.<sup>2,3</sup> This article focuses on the changing method for today's caries management, using evolving new concepts and techniques.

## **CARIES-MANAGEMENT GUIDELINES**

Dental caries has a new definition. In 2001, the National Institute of Health's (NIH) Consensus Conference on the Diagnosis and Management of Dental Caries Throughout Life concluded:

"Dental caries is an infectious, communicable disease resulting in destruction of tooth structure by acid-forming bacteria found in dental plaque, an intraoral

biofilm, in the presence of sugar. The infection results in the loss of tooth minerals that begins with the outer surface of the tooth and can progress through the dentin to the pulp, ultimately compromising the vitality of the tooth."<sup>4</sup>

This statement combines a number of new components from the traditional approach taught over the last 20 years in dental schools. Our patients assume that tooth decay is caused by eating sugary foods, not that dental caries is an infectious, communicable disease caused by acid-forming bacteria. Patients, along with us, have the opportunity to look anew at how we diagnose, prevent, and treat dental caries.

Based on the "medical" — preventive and less "surgical" — intervention model of caries, the appropriate management of caries has been called for in an increasing number of dental guidelines. A 2000 Federation Dentaire Internationale paper discusses a revised model for

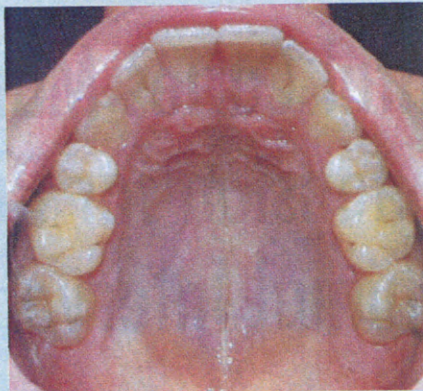
caries control consistent with the philosophy of minimal intervention dentistry:

- Early caries detection and diagnosis.
- Caries risk assessment and reduction of bacteria.
- Medical model approach of caries reduction, including use of fluorides and reduction of bacteria. This includes monitoring for remineralization of suspicious areas.
- Arresting active lesions.
- Placing restorations with minimal cavity design.
- Repairing, rather than replacing, existing restorations.<sup>5</sup>

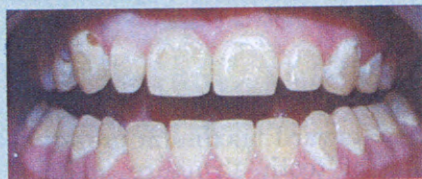### CARIES RISK ASSESSMENT

Traditionally, we have identified carious lesions and begun surgical treatment of large lesions without dealing with the underlying pathology (Fig. 1 & 2). At the first appointment, in addition to a dental examination, a risk assessment for caries and bacterial reduction is essential. Practice protocol must establish the "cause" of the infection. This discovery will determine whether a medical, surgical, or combination model of intervention should be used. We must always keep in mind that dental caries requires teeth, bacteria in a biofilm, and a steady diet of carbohydrates in order to create a lesion. At times, acidic media and parafunctional forces will also enhance the caries process. Identifying these factors is part of the caries risk assessment. One of the most recent caries risk assessments was published in the *Journal of the California Dental Association* in 2003.<sup>6</sup> It provides both a template for caries risk assessment and some educational tools for patients. This can give you a starting place for creating your own series of tools and assessments for your practice.

A new system for defining caries, beginning with subclinical decay to pulpal decay, has been developed by Pitts<sup>7</sup> (Fig. 1). He has defined caries with four major classifications:



**FIGURE 1**—Example of full-mouth demineralization/remineralization.



**FIGURE 2**—Classic ortho debanding. Photos by Dr. Lori Trost.

1. Subclinical decay.
2. Visible and invisible enamel decay.
3. Visible and invisible dentin decay.
4. Pulpal decay.

These four stages have implications for today's treatments.<sup>8</sup> Figure 3 is an adaptation of the above reference, and Figure 4 shows how each of these four stages fits into a system of assessment and treatment. Each stage corresponds to either a medical treatment model, a surgical intervention model, or a combination. Medical management predominates for subclinical and enamel decay, while surgical intervention predominates for dentin decay and pulpal decay.

We as a profession should focus

on both the surgical management of the lesion as well as the potential to detect and remineralize early lesions before they require surgical intervention. We should not be surgically treating early carious lesions, but rather helping to promote remineralization of these lesions.

### STAGING THE DISEASE

Mount and Hume have devised a system for caries classification.<sup>9-12</sup> The chart in Figure 5 would allow the practitioner to rate caries by location (or size site) and degree of caries involvement.

There are only three locations for decay on a tooth surface:

1. Pits and fissures.
2. Contact areas.
3. Cervical areas.

As caries progresses in these areas, the size of the surgical intervention will increase. Sizes of decay would be:

1. Initial lesion, with possible medical intervention.
2. Decay beyond remineralization.
3. Decay undermining cusp or possible cusp fracture due to decay.
4. Loss of cusp or incisal edge.

Each classification has a corresponding different approach to cavity preparation. Mount has provided an excellent description in his paper published in *Operative Dentistry* in 2003.<sup>12</sup>

### DIAGNOSIS OF DENTAL CARIES

Early diagnosis of dental caries does not mean early surgical treatment. Our traditional methods of diagnosis — explorer, dry field mirror, and radiographs — really detect well-advanced lesions. With new techniques for assessment already in the marketplace and technology just being developed, we will be able to




FIGURE 3




FIGURE 4

detect early lesions that do not require surgical intervention but may be treated with other noninvasive methods. We can begin to apply these methods today as we await these new devices.

### REDUCING BACTERIAL POPULATIONS

Dental caries arises from an overgrowth of specific bacteria that can metabolize fermentable carbohydrates and generate acids as waste products of their metabolism. *Streptococci mutans* and *Lactobacillus* are the two principal species of bacteria involved in dental caries and are found in the plaque biofilm on the tooth surface.<sup>13-15</sup> When these bacteria produce acids, the acids diffuse into tooth enamel, cementum, or dentin and dissolve or partially dissolve the mineral from crystals below the surface of the tooth. If the mineral dissolution is not halted or reversed, the early subsurface lesion becomes a "cavity." If we can control or reduce the bacterial populations, we should reduce the chances of forming additional lesions or allowing existing lesions to increase in size (Fig. 6).

Current rinses used to decrease caries-causing bacteria include the following:

Chlorhexidine gluconate used two times per day for two weeks. High-risk patients might continue this regimen for up to one year.

Betadine may be used as an

alternative rinse. This one-minute rinse kills the caries-producing bacteria for three to four months.

### PROMOTING REMINERALIZATION

Dental caries is really a fine balance between demineralization and remineralization. The tooth surface will undergo periods of demineralization and remineralization depending upon the acidity of the surrounding environment. The balance between demineralization and remineralization is determined by a number of factors. Featherstone describes this as the "Caries Balance," or the balance between protective and pathological factors (Fig. 6).<sup>16</sup>

Whether a medical or surgical model is chosen, remineralization strategies should be considered. The following are current remineralization products:

- Prospec MI Paste (GC America) — a good-flavored and easily applied cream (CCP-ACP) technology that contains Recaldent.<sup>TM</sup> This paste can be used as a daily toothpaste and works specifically by releasing calcium and phosphate in an acid-challenged environment during the demineralization/remineralization process.
- ACP — Amorphous calcium phosphate is classified in a new series of "smart materials." Research has shown that ACP can,

as needed, trigger the slow release of calcium and phosphate ions and has also demonstrated the ability to re-mineralize tooth structures. As a result, these "smart materials" may have the ability to enhance the teeth's natural repair mechanism.

- Novamin paste — a bioactive glass that has shown in-vitro results for remineralization at the March 2005 American Association of Dental Research meeting.<sup>17</sup>

- Fluoride varnishes - sodium fluoride in a resin carrier applied directly to the area by brush/sponge. Brands include: Cavity Shield (OMNII), Duraphat (Colgate-Palmolive), Duraflor (A.R. Medicom), and Fluor Protector C (Ivoclar Vivadent).

- High-dosing fluoride rinses, gels, and toothpastes — dispensed by prescription; a large variety available.

### ORAL HYGIENE, HOME CARE, AND DIET

Even with these new advances, there is no replacement for daily proper brushing and flossing to remove the bacterial biofilm and apply a topical layer of fluoride on the tooth surface. This is one of the basic tenets of dentistry, which should continue to be promoted to our patients along with the value of a proper diet low in carbohydrates. We should also discuss the timing of the intake of carbohydrates and other acidic foods.

### CAVITY PREPARATION

The advancement of bonding materials (adhesives and resin materials) necessitates a different approach to cavity preparation and design. The "accepted and taught" G.V. Black theory of "extension for prevention" cavity preparation becomes obsolete.<sup>18</sup> Each cavity preparation becomes distinctive, determined by the extent of the lesion, not a previ-

Size Site	New Caries Classification (G. Mount)				
	0	1	2	3	4
1	1.0.	1.1.	1.2.	1.3.	1.4.
2	2.0.	2.1.	2.2.	2.3.	2.4.
3	3.0.	3.1.	3.2.	3.3.	3.4.

Used by permission of Operative Dentistry

FIGURE 5

ously determined cavity outline. The maximum amount of tooth structure is preserved, with a goal of tooth integrity.

The most important physical property when considering bonding material is the strength of the material and the bond to tooth structure. This bonded relationship to the surrounding tooth further supports the theory for minimal tooth preparation and no longer is dependent on design undercuts for retention of the restoration. Dr. Mount's approach to cavity preparation takes this into account. This change in mindset and confidence in restorative materials calls for the cavity preparation no longer to be restored subjectively, but tooth structure to be preserved for longevity and strength. In reality, cavity preparation should be dictated solely by the extent of the lesion with retention of the restoration being dependent upon adhesion to the remaining tooth structure.

There are also new instruments to help us prepare small preparations. SS White has designed Fissurotomy Burs that allow the clinician to prepare very small occlusal fissures. Their triangular-shaped bur allows you to open and explore suspect fissures.<sup>19</sup> Smart Burs, polymer burs from SS White, are designed to remove only the infected dentin, leaving behind the unaffected dentin.<sup>20-22</sup> With this conservative tissue removal, one can avoid pulp exposure in deep preparations and/or minimize the amount of tooth structure removed when removing infected carious

tissue. These two burs are examples of the types of instrumentation that can be used for minimally invasive surgical treatment.

### STANDARD OF CARE

The appeal of minimally invasive dentistry is that it proposes a viable evidence-based standard of care.<sup>23</sup> The Cochrane Collaboration and dental organizations, including the ADA, have endorsed evidence-based care, so the goal of minimal intervention completely supports this policy. However, the mindset of the dental community must also change to accept this new philosophy and confirm use of current materials and diagnostics, while using appropriate coding and reimbursement. Furthermore, new treatment protocols must be designed to respond to our current understanding of the importance of the prevention medical model, even when used in conjunction with traditional surgical approaches. Reimbursement issues will drive this in the future.

### ETHICS AND THE PATIENT'S RIGHT TO KNOW

Given a choice, patients usually elect nonsurgical treatment. With the growing health debate and rising awareness of the importance of prevention, patients will begin to question why restorative (surgical intervention) is chosen, repeated, or perhaps offered with no alternative treatment. It becomes essential for the contemporary dentist to propose and support alternative methods of caries diagnosis, medical management/prevention, and intervention.

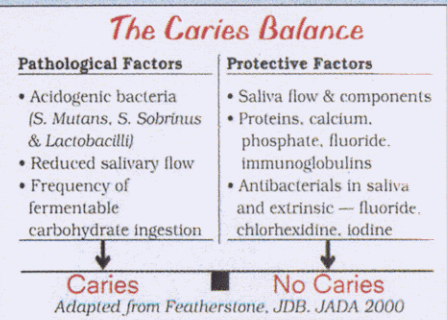


FIGURE 6

### POLICY PERSPECTIVES ON REIMBURSEMENT ISSUES FOR EVIDENCE-BASED DENTISTRY

Today's evidence on minimally invasive dentistry is clear. However, there is a lag in information flow between current accepted dental procedures and current evidence-based dentistry clinical standards from state boards to dental practice.<sup>23</sup>

The conductivity of information about minimally invasive dentistry has been impeded by a number of factors. First, scientific information moves slowly from rarely read journals by busy practitioners who cannot change their systems quickly to the current designs of continuing-education programs that focus on popular figures, not necessarily scientific experts.

Reimbursement may be the biggest barrier to adoption of minimally invasive dentistry in the United States. In a 24/7 news and information world, it is hard to believe that accepted dental coding standards are reviewed every two years. Yet they are. For example, with two caries-detection devices on the market in the United States, these could not be reviewed for coding for reimbursement until 2007. Even G.V. Black would be horrified that artificial intelligence in today's information age isn't being used to provide reimbursement for evidence-based dentistry. The authors are concerned that strength of

evidence is not driving today's reimbursement, nor is the process nimble enough to accommodate today's — much less tomorrow's — needs to serve patients.

A recent article notes that many administrative decisions, such as decisions about coverage, claim to be "evidence based," rather than usual practice in an area or type of service delivered.<sup>26</sup> We believe that this could be applied to dentistry. For dentistry, change must become the norm and the only constant in today's practice. Committees who make decisions about coding issues, state boards, dentists, and dental payors must all concur on principles of evidence-based dentistry and greater responsiveness to provide the highest level of service to our patients. Ethics and professional practice demand that we do no less.

Minimal intervention is definitely not extension for prevention. It is an evolution in our approach to the assessment, diagnosis, and treatment of dental caries.<sup>27</sup> It is designed to save tissue and potentially "heal" or remineralize lesions. It does include a surgical approach to lesion management, but this is not the focus. As new techniques become available to our profession, we need to adopt this approach to care and actively promote it to our patients. Minimal intervention should become as common as tooth-brushing. Minimal intervention involves patients and dentists actively participating to manage and control carious lesions. **OH**

*Dr. Abrams is a partner in a group practice in Scarborough, Ontario, Canada. For five years, he has been involved in the research and develop-*

*ment of a laser-based system for caries diagnosis. He is the founder of Four Cell Consulting. Contact him at dr.abrams@cell@sympatico.ca.*

*Dr. Scarlett is the science and women's health editor of Woman Dentist Journal. An accomplished clinician, scientist, and lecturer, she is retired from the Centers for Disease Control and Prevention. You may contact her by email at megscarlett@mindspring.com.*

*Dr. Trost is the managing editor of Woman Dentist Journal. She created the Center for Contemporary Dentistry in Columbia, Ill., in 1989. She is a member of the ADA and AGD. You may contact Dr. Trost at lorit@pennwell.com.*

*Reprinted with permission, Woman Dentist Journal, March, 2005. References available upon request.*

©ARTICLECATEGORY:583

## Satisfied with your practice ROI?

In-office practice assessment  
Facilitation  
Professional Training  
Seminars  
Associate Recruiting

~ the return on investment was swift, consulting services were delivered in a timely, effective manner~  
Dr. Armit Puri, Toronto, Ontario

~ each team member had an opportunity to grow within the practice learning more about themselves and the importance of a unified team~  
Laura, Office Manager, Burlington, Ontario

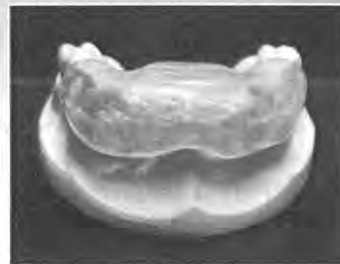

Call us today!  
1-888-454-1373

## INTRODUCING THE DEPROGRAMMER

We would like to introduce you to an interesting new product. Our deprogramming splint is designed to allow only central incisor contact in all excursions. This therapeutic function stimulates the body's natural reflex protection to calm the powerful temporalis muscles and suppress the active lateral pterygoid muscles.

The device provides chronic pain relief and is gaining popularity among our customers. The deprogrammer is professionally fabricated from Eclipse™ light cure material, custom designed for retention, and is both comfortable and small.



For more information or to find out how you can get a sample splint to show your patients, contact Joanne Friedman.

**DSC** Dental Services Group  
of Toronto

A DENTAL SERVICES GROUP LABORATORY

572 Champagne Drive  
Toronto, Ontario M3J 2T9  
Phone 416-654-6365 or 1-800-268-1860  
dsgtoronto@dental-services.net

Visit us at the ODA Meeting, Booth # 1618